

Maternal-Fetal Transmission of the Lyme Disease Spirochete, *Borrelia burgdorferi*

PETER A. SCHLESINGER, M.D.; PAUL H. DURAY, M.D.;
BARBARA A. BURKE, M.D.; ALLEN C. STEERE, M.D.; and M.
THOMAS STILLMAN, M.D.

Hennepin County Medical Center and the University of
Minnesota Medical School, Minneapolis, Minnesota; Yale
University School of Medicine, New Haven, Connecticut.

LYME DISEASE usually begins with a characteristic skin lesion, erythema chronicum migrans, accompanied by "influenza-like" or "meningitis-like" symptoms (1). Some patients later develop cardiac abnormalities such as atrioventricular heart block or myopericarditis, neurologic complications, or intermittent attacks of arthritis (1). The causative agent, the Lyme disease spirochete *Borrelia burgdorferi* (2), is transmitted by *Ixodes dammini* or related ixodid ticks (3). Antibiotic treatment with tetracycline or penicillin is usually curative (4).

We report the case of a woman who developed Lyme disease during the first trimester of pregnancy. She did not receive antibiotic therapy. Her infant, born at 35 weeks gestational age, died of congenital heart disease during the first week of life. Histologic examination of autopsy material showed the Lyme disease spirochete in the spleen, kidneys, and bone marrow.

A 28-year-old mother of two healthy children became pregnant for the third time in September 1983. Soon thereafter, she participated in outdoor activities in an area of northwestern Wisconsin known to be endemic for Lyme disease (3). On 7 November 1983, she noted an expanding annular skin lesion in the left popliteal region reaching a size of 20 × 30 cm. She also developed two secondary skin lesions, headache, stiff neck, arthralgias, malaise, and inguinal lymphadenopathy. All symptoms resolved within several weeks without treatment. Thereafter, the antepartum course was normal except for recurrent arthralgias during the third trimester. No medications were taken during the pregnancy.

On 6 May 1984, the patient delivered a 3000-g male infant whose estimated gestational age was 35 weeks. No skin lesions were seen. The baby had respiratory distress. An echocardiogram and cardiac catheterization showed a dilated, poorly contractile left ventricle; aortic valvular stenosis; patent ductus ar-

teriosus; and coarctation of the aorta. Despite emergency balloon catheter dilatation of the coarctation and aortic valvotomy, the infant died after 39 hours.

Five days postpartum, the mother developed arthritis of the left wrist and right knee and right Achilles tendinitis. Analysis of a right knee aspirate showed leukocytes, 13 200/mm³, with 93% neutrophils and 7% monocytes, and negative culture. The erythrocyte sedimentation rate was 52 mm/h. Her serum IgG antibody titer to *Borrelia burgdorferi* was 1:128 (normal, 1:64 or less), determined by indirect immunofluorescence (Rocky Mountain Laboratories, Hamilton, Montana). Results of a urinalysis, complete blood count, test for rheumatoid factor, and a serologic test for syphilis were normal or negative. The patient was treated with aspirin and tetracycline, 2 g/d for 10 days, and has not had arthritis during the subsequent 8 months.

An autopsy of the infant showed widespread congenital cardiovascular abnormalities. Tubular hypoplasia of the ascending aorta and aortic arch, marked endocardial fibroelastosis, and a persistent left superior vena cava draining into the coronary sinus were found. There was no evidence of inflammation, necrosis, or granuloma formation in the heart or other organs. The placenta was not available for study. Paraffin block sections of the viscera were stained later by a modification of the Dieterle method (5). A few spirochetes, morphologically compatible with the Lyme disease spirochete (6), were found in the spleen, renal tubules, and bone marrow (Figure 1), but not in the heart. Many oil immersion fields were examined to identify the spirochete, and never more than one organism was seen in a given field.

In Lyme disease, *B. burgdorferi* is injected into the skin at the site of the tick bite and appears to spread hematogenously early in the disease (2). The Lyme spirochete has been cultured from blood, skin, and cerebrospinal fluid (2) and has been seen in synovial lesions (6). In experimentally infected hamsters, the organism has been isolated from the spleen, eyes, kidneys, liver, testes, and brain (7). Although the number of spirochetes in blood and affected tissues appears to be low, it is clear that the organism may invade and persist in many different sites.

The Lyme disease spirochete may also spread transplacentally to organs of the fetus. The mother in this case developed Lyme disease during the first trimester of pregnancy; spirochetes were seen in the spleen, kidney, and bone marrow of the infant at term. In addition, the infant had several cardiovascular abnormalities. However, no

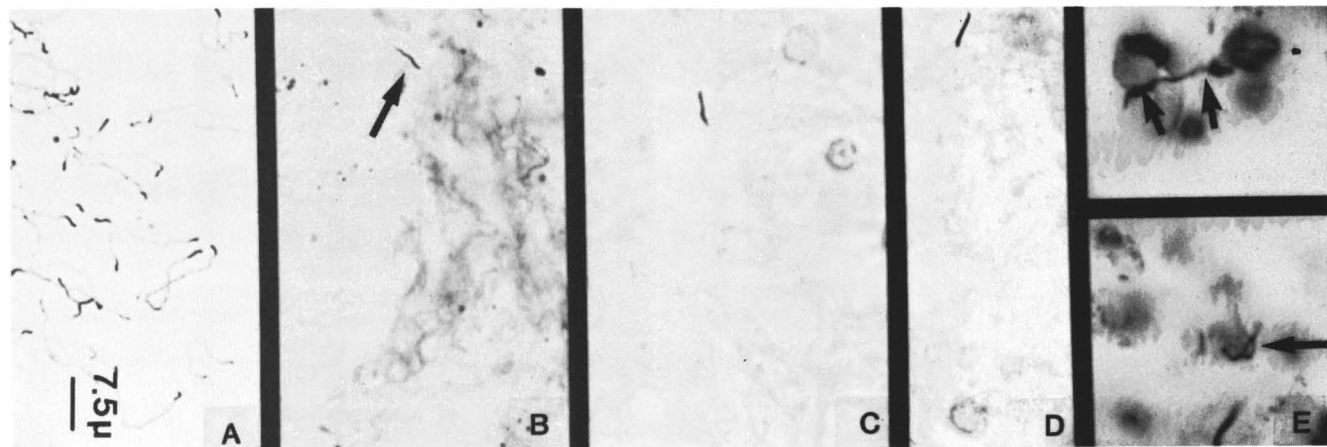


Figure 1. Photomicrographs of *Borrelia burgdorferi*: maintenance culture (Barbour-Stoenner-Kelly medium) showing long and shorter forms (A); autopsy spleen sample showing a single spirochete (arrow) near a fibrous trabeculum (B); proximal convoluted renal tubules showing *B. burgdorferi* (C, D) (note the absence of inflammatory cells); and spirochetes in sections of bone marrow (arrows), with the top photomicrograph showing a particularly long spirochete (E). All sections stained by a modified Dieterle silver impregnation method (original magnification, × 1250).

spirochetes were found in his heart, and no organ inflammation was seen. In contrast, in congenital syphilis affected tissues show mononuclear cell infiltration and fibroblast proliferation (8); cardiac malformations have not been reported. The maturing fetal immune response to *Treponema pallidum*, not the spirochetemia itself, is thought to be responsible for disease expression in the second half of gestation (8). It is unclear whether *B. burgdorferi* played any role in the congenital heart disease that led to this infant's death. However, because the fetus is likely to have been infected during cardiovascular organogenesis, which occurs at 18 to 60 days of gestation (9), a teratogenic effect of the spirochete cannot be excluded.

Women who acquire Lyme disease while pregnant should be treated promptly with penicillin, or if allergic, erythromycin, 250 mg orally four times a day for 10 to 20 days. At the time of childbirth, the placenta should be examined for histologic abnormalities and for spirochetes, as in congenital syphilis (10). If the infant is ill, the diagnosis of congenital Lyme disease should be considered. Finally, it may be prudent for pregnant women to avoid tick exposure in endemic areas during the summer months.

ACKNOWLEDGMENTS: The authors thank Rachelle Cherkawi for manuscript preparation, Adele Kusnitz for tissue sectioning and staining, Robert Specht for the photomicrography, and Dr. Jesse E. Edwards for assistance in the cardiac examination.

Grant support: in part by grant AM-20358 from the U.S. Public Health Service.

► Requests for reprints should be addressed to Peter A. Schlesinger, M.D.; Department of Medicine, Hennepin County Medical Center, 701 Park Avenue South; Minneapolis, MN 55415.

REFERENCES

1. STEERE AC, MALAWISTA SE, HARDIN JA, RUDDY S, ASKENASE PW, ANDIMAN WA. Erythema chronicum migrans and Lyme arthritis: the enlarging clinical spectrum. *Ann Intern Med.* 1977;86:685-98.
2. STEERE AC, GRODZICKI RL, KORNBLATT AN, et al. The spirochetal etiology of Lyme disease. *N Engl J Med.* 1983;308:733-40.
3. STEERE AC, MALAWISTA SE. Cases of Lyme disease in the United States: locations correlated with distribution of *Ixodes dammini*. *Ann Intern Med.* 1979;91:730-3.
4. STEERE AC, HUTCHINSON GJ, RAHN DW, et al. Treatment of the early manifestations of Lyme disease. *Ann Intern Med.* 1983;99:22-6.
5. VAN ORDEN AC, GREER PW. Modification of the Dieterle spirochete stain. *J Histotechnol.* 1977;1:51-3.
6. JOHNSTON YE, DURAY PH, STEERE AC, et al. Lyme arthritis: spirochetes found in synovial microangiopathic lesions. *Am J Pathol.* 1985;118:26-34.
7. JOHNSON RC, MAREK N, KODNER C. Infection of Syrian hamsters with Lyme disease spirochetes. *J Clin Microbiol.* 1984;20:1099-101.
8. OPPENHEIMER EH, HARDY JB. Congenital syphilis in the newborn infant: clinical and pathological observations in recent cases. *Johns Hopkins Med J.* 1971;129:63-82.
9. NORA JJ. Etiologic aspects of heart diseases. In: ADAMS FH, EMMA-NOULIDES GC, eds. *Moss' Heart Disease in Infants, Children, and Adolescents*. 3rd ed. Baltimore: Williams and Wilkins; 1983:2-10.
10. RUSSELL P, ALTSHULER G. Placental abnormalities of congenital syphilis: a neglected aid to diagnosis. *Am J Dis Child.* 1974;128:160-3.

©1985 American College of Physicians